

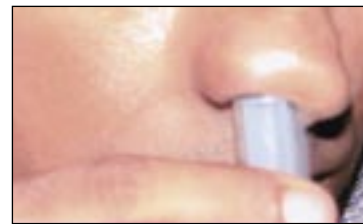The *Annals of Saudi Medicine* welcomes letters from readers that comment on recent articles published in the journal. They should be received within six weeks of the publication of the article and be not more than approximately 500 words. Send letters to [jtcathey@kfshrc.edu.sa](mailto:jtcathey@kfshrc.edu.sa). They should not be submitted as manuscripts on the journal's online manuscript submission site.

**Surgical pearl:  
A disposable syringe  
barrel is a better  
alternative to a Foley's  
catheter for intra-  
operative nasal ala  
stabilization.**

**To the Editor:** The nasal ala is one of the most frequent surgical sites for Mohs surgeons and for cosmetic surgeons. To perform accurate and elegant surgery over the ala, the skin surrounding the lesion needs to be stretched and fixed.<sup>1,2</sup> Stretching the skin around skin lesions on the nasal ala is problematic because it lacks underlying bony and or fibrous tissue. There are several techniques, such as insertion of the tip of the finger into the nasal antrum, insertion of the back of the scalpel or the back of the forceps, and insertion of gauze and a Foley catheter, that are used to stretch and stabilize the ala.<sup>1,2</sup> The use of a Foley catheter is a bit better and safer but it is expensive and the site cannot be manipulated during the operative procedure, which is sometimes desired by surgeons and dermatologists to get an optimum stretch at a particular site of the ala. Secondly, in making a deep incision in the case of skin cancers over the nasal ala, the catheter can get nicked, which may be a cause for hindrance during the operation. In addition, the catheter cannot be used at the

same time for both nostrils due to air passage blockage. These drawbacks of the Foley catheter can be minimized by inserting the inexpensive and readily available barrel of a disposable syringe into the nasal antrum during excision, in cosmetic as well as reconstructive surgery of the nasal alae.

I take different sizes of disposable syringes (1, 3, 5 or 10 mL) and then measure the outer diameters of the barrels from the piston side of the syringe. Their respective diameters are 8 mm, 12 mm, 17 mm, and 18 mm, but there are slight variations by manufacturer. The nostril diameter is measured tentatively, for a better assessment of the optimum size of the barrel, with the help of a fine forceps or calipers after stretching the hands gently in the nostril in the antero-posterior and in vertical to antero-posterior direction. The calipers or forceps are inserted in the nostril outwardly and the distance between two hands in the stretched state is measured in millimeters. The average diameter in each direction is the effective diameter of the nostril. Thus, the size of the barrel should be chosen according to the diameter of the nostril. Following this, the size of the lesion and its excision line are marked and anesthesia is obtained by injection xylocaine (1% with adrenaline 1:200 000) at the operative site over the ala for localized and small lesions or by general anesthesia for major reconstructive surgery on the alae. Then the barrel is inserted into the nostril from the needle hub side of the syringe, after removing the needle, by a gentle screwing movement until the site of operation becomes stretched, and the piston of the syringe is removed (Figure 1). If the patient is feeling unease during insertion of the



**Fig 1.** Barrel of disposable syringe inserted into the nasal antrum for its stabilization

barrel particularly, which is rarely needed, in case of operative surgery under local anesthesia, then xylocaine can be sprayed with the help of the same syringe or by a spray unit, or jelly can be applied over the barrel surface before inserting the barrel of the syringe. For better air passage, if needed, the distal portion of the syringe with its needle hub can be cut before insertion of the barrel.

For peri-operative stabilization and manipulation of the nasal ala, the barrel of a disposable syringe is a simple, readily available and inexpensive instrument. It can be manipulated during the operation according to needs, which is difficult with the catheter.<sup>1,2</sup>

*I am very thankful to Mrs. Safia Akhtar for her encouragement and assistance in this article.*

**Muhammed Mukhtar, MD**  
Consultant Dermatologist  
Sofia Skin Centre  
13/289, Wazidpur  
Patna 803213  
India  
[muhammedmukhtar@hotmail.com](mailto:muhammedmukhtar@hotmail.com)

## References

1. Alcalay J, Goldberg LH. Intraoperative nasal ala stabilization using the Foley catheter. *J Dermatol Surg Oncol.* 1991;17:957-958.
2. Alcalay J. Intraoperative nasal ala immobilization using the Foley catheter. In: Harahap M, ed. *Innovative techniques in skin surgery.* New York: Marcel Dekker 2002;95-102.

### Value of ophthalmic features as a means of diagnosis of HIV/AIDS infection

**To the Editor:** The acquired immune deficiency syndrome (AIDS), first reported in 1981, is a ravaging pandemic on all continents, particularly in developing countries, where nearly 100 million people are affected, including about 5.4% of Nigerians.<sup>1,2</sup> Patients with AIDS are likely to develop some form of ocular involvement during the course of illness, with approximately half presenting with ocular features of this disease.<sup>1</sup> This is a special challenge for the ophthalmologist, requiring special knowledge.<sup>3</sup> A study in Romania found that about 70% had AIDS-related ocular involvement, but this HIV-related complication is now uncommon in the industrialized nations because of better quality of life and treatment.<sup>4</sup> This is not the case in Sub-Saharan Africa, particularly in Nigeria. The majority of HIV positive/AIDS patients in Nigeria have no access to highly active antiretroviral treatment (HAART), which is generally available in Western countries.

We conducted a study aimed at documenting early ocular features of HIV/AIDS. Awareness of these features could help in early diagnosis and treatment of the infection. Between January 1999 and December 2002, 3776 new patients were seen at the eye clinic of Obafemi Awolowo University Teaching Hospital, Ile-Ife. All had a comprehensive ophthalmologic examination using slit lamp examination, direct and indirect funduscopy, and refraction among others. Other associated systemic features that constitute the symptoms and signs of clinical AIDS

were identified based on WHO HIV/AIDS defining criteria. Patients were given pre- and post-test counseling by trained nurses, and serologic tests for HIV screening. Biopsy of the conjunctiva lesions was done after obtaining informed consent. Testing for HIV-1 and HIV-2 antibodies was done using ELAVIA-2, with confirmation by the Western immunoblot method in HIV positive patients. All patients with herpes zoster ophthalmicus and skin lesions were further managed by the dermatologist.

Of the 3776 new patients, 11 (0.29%) were found to be HIV positive. These represented 1.7% of the 680 HIV/AIDS patients diagnosed at the hospital during the study period. There were 7 males and 4 females (1.75:1 ratio). Ages ranged from 16 to 56 years, with a mean (+SD) age of 32±2.7 years. One had squamous cell carcinoma of the conjunctiva, and 4 (36.4%) had herpes zoster ophthalmicus (3 males and 1 female). One had lateral rectus muscle palsy and associated optic atrophy. Two patients (18.2%) had bilateral anterior uveitis, one had right panuveitis with rubeosis iridis. Diagnosis of retinopathy was made in two patients. None of the patients was placed on HAART due to financial constraints and lack of access to HAART. The majority (54.6%) of the HIV patients defaulted while the others were referred to other specialists for further management.

The results confirm that without a high index of suspicion, a number of HIV/AIDS patients presenting in the eye clinic would go undiagnosed. Our findings confirm the observation of other workers that herpes zoster infection in apparently healthy-looking young adults is a marker of

HIV infection in Africa.<sup>5,6</sup> Two patients had HIV-related retinopathy. One had generalized retinal oedema with a few cotton wool spots (CWS) and a lot of hemorrhages while the other had macular oedema and retinal hemorrhages. She later developed frank cutaneous herpes zoster before she defaulted from the eye clinic. HIV retinopathy, a non-infectious microangiopathy has been reported as the most common ocular manifestation of HIV infection while opportunistic ocular infections, particularly CMV retinitis, are a major cause of morbidity in patients with AIDS.<sup>7</sup> Most patients with HIV disease demonstrate CWS at some point during their illness. The presence of CWS in healthy HIV positive patients has relatively little clinical significance, but the presence of CWS in patients with very low CD4 counts and advanced HIV disease is a negative prognostic sign.<sup>1</sup> The association of HIV with certain malignancies, such as Kaposi's sarcoma and squamous cell carcinoma (SCC) of the conjunctiva, has been well documented in Malawi<sup>1</sup> and Rwanda.<sup>5</sup> SCC of the conjunctiva may be the only manifestation in an otherwise healthy-looking adult.<sup>1</sup> Also, in this study, SSC of the conjunctival and right lateral rectus muscle palsy with associated optic atrophy were seen as isolated lesions.

The fact that a significant percentage (1.7%) of HIV/AIDS cases diagnosed in the hospital came through the eye clinic argues for greater attention to the diagnosis of this scourge during presentation to the eye clinic. We advocate a massive public health enlightenment of the general population on HIV/AIDS. Furthermore, we hope that African governments will develop the political will to

provide HAART to the teaming population of patients with AIDS.

#### B. O. Adegbehingbe

Ophthalmology Unit  
Department of Surgery  
College of Health Sciences  
Obafemi Awolowo University  
Ile-Ife, Nigeria

#### A. O. Olasode

Department of Dermatology  
and Venerology  
College of Health Sciences  
Obafemi Awolowo University  
Ile-Ife, Nigeria

#### Correspondence:

#### Dr. B. O. Adegbehingbe

berniceola2003@yahoo.com.uk  
Tel: 234-803-721-8094

#### References

1. Kestlyn PG, Cunningham ET. *HIV/AIDS and Blindness*. Bull World Health Organization. 2001;79:208-213.
2. *National Action Committee of AIDS Bulletin*. December 2003. Nigeria
3. Nicu C. The ocular manifestations in the acquired immunodeficiency syndrome. *Ophthalmologia*. 1991;35(2):20-9.
4. Fabricus EM. Epidemiology of HIV infection. *Klin Monatsl Augenheilkd*. 1993;202:460-4.
5. Kestlyn P, Stevens AM, Baker E, Rourroy D, Van de Perre P. Severe herpes zoster ophthalmicus in young African adults as marker for HLTV III seropositivity. *S. J Ophthalmol*. 1987;71:806-9.
6. Ekweozor CC, Olalaye OD, Tomori O, Saliu I, Esian EM. HIV sentinel surveillance in Ibadan/Ogbomoso zone of Oyo State. A pilot study. *Nig Med J*. 1993;1-4.
7. Tay-Keany MI, Jabs DN. Ophthalmic complications of HIV infection. *Med Clin North Am*. 1996;80:1471-92.

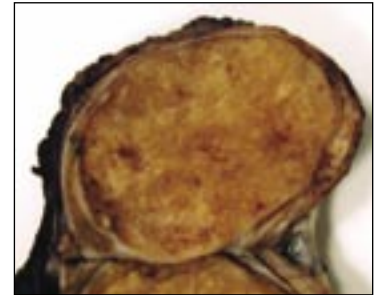
### Large cell calcifying Sertoli cell tumor of the testis

**To the Editor:** Large cell calcifying Sertoli cell tumor of the testis (LCCSCT) is a rare sex cord-stromal tumor that is usually benign,<sup>1,2</sup> however, recently there have been reported cases with malignant features.<sup>3</sup> In a literature review, there were 68 cases of LCCSCT and 10 of those showed malignant

features. Patients may have associated endocrine abnormalities, and tumors tend to be bilateral and multifocal.<sup>2,3</sup> These tumors usually occur in children and adolescents, and occur rarely in patients over 40 years of age.<sup>1-5</sup> They are reported in patients from 2 to 73 years of age (average, 21 years).<sup>1,2,6</sup> We report two further cases.

The first case was a 26-year-old male who presented with a painless lump in the left testicle that he felt over the past few days prior to presentation. Scrotal ultrasonography (US) revealed an irregular circular outlined hyperechoic heterogeneous solid lesion located at the lower posterior aspect of the left testicle showing features of calcified fibrosis. It measured 19 mm in maximum diameter. Hormonal assay showed normal follicle stimulating hormone/luteinizing hormone (FSH/LH), testosterone, alpha-fetoprotein and beta human chorionic gonadotropin ( $\beta$ -hCG) were normal in the blood. The patient was treated by lumpectomy with a surgical margin. The second case was a 4½ year-old male who presented with a 2-year history of precocious puberty, excessive growth and right testicular mass. Hormonal assay showed normal FSH/LH and  $\beta$ -hCG. There was a high testosterone level. US reveal a large mass of heterogeneous density. The patient was treated by orchidectomy. There was no history of trauma or inflammation in either patient. Figure 1 shows the gross picture of the first case. Microscopically, both tumors showed similar features. Sections revealed well-circumscribed and composed solid sheets, nests, trabeculae, cords, and small clusters with a rare attempt at tubular formation (Figure 2a, b, c, d). The tumor cells were polygonal, having defined outlines with abundant

acidophilic cytoplasm, with occasional clear cytoplasm, a round or oval nucleus with some nuclear pleomorphism. The stroma varied from loose and myxoid to densely collagenous. Multiple areas of calcification with psammoma bodies were seen. There was no evidence of necrosis or mitosis.



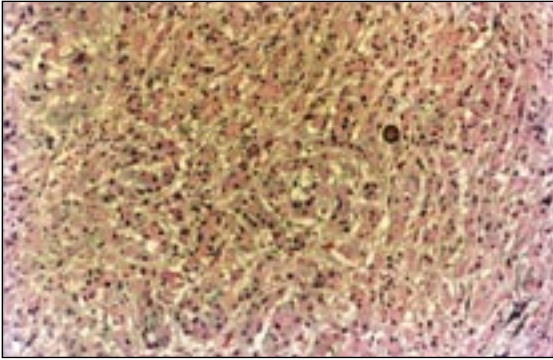
**Figure 1.** Gross picture from the testicular tumor of case #2 showing a well-circumscribed tumor measuring 5 cm in maximum diameter, grayish yellow in appearance with no evidence of hemorrhage or necrosis.

Our two cases were microscopically misdiagnosed initially as Leydig cell tumor. Historically, the confusion between a Sertoli cell tumor in the large cell calcifying category and a Leydig cell tumor has been particularly problematic. Before the former tumor was recognized it was often misdiagnosed as a Leydig cell tumor. There were strong associations of malignant behavior with size >4 cm, extratesticular growth, gross or microscopic necrosis, high-grade cytological atypia, vascular space invasion, and a mitotic rate greater than three mitoses per 10 high-power fields.<sup>7</sup> These reports appear to be the first cases of LCCSCT reported from Saudi Arabia.

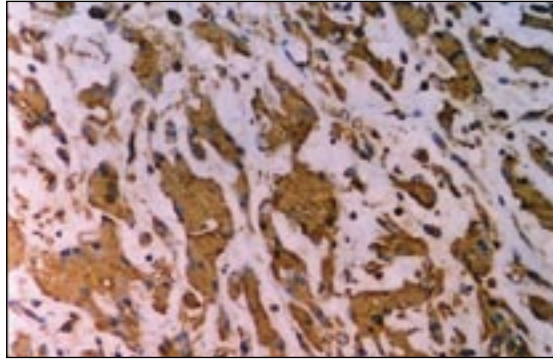
#### Jaudah A. Al-Maghrabi

Fadwa Altaf  
Abdulmalik Al-Tayib  
Hisham Mosli  
Department of Pathology

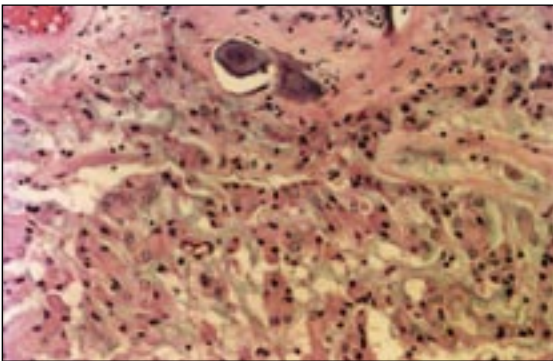




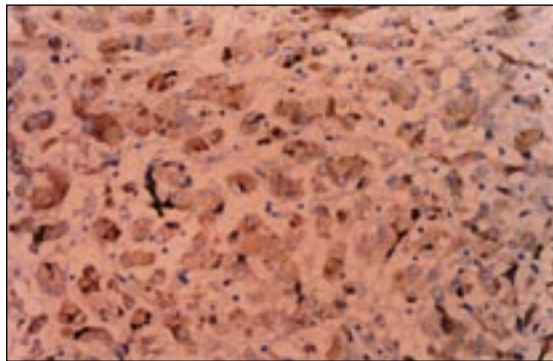
**Figure 2A.** Section from the neoplasm show solid sheets, nests, trabeculae, and cords of polygonal cells (H&E, X100).



**Figure 2C.** Immunohistochemical stain showing a strong positivity for vimentin (Immunohistochemistry, X200).



**Figure 2B.** Higher power section from the neoplasm (H&E stain, X200)



**Figure 2D.** Immunohistochemical stain showing a weak positivity for inhibin (Immunohistochemistry, X200).

King Faisal Specialist Hospital  
& Research Centre–Jeddah  
MBC J-10  
PO Box 40047  
Jeddah, Saudi Arabia  
jalmaghrabi@hotmail.com

## References

1. Proppe KH, Scully RE. Large-cell calcifying Sertoli cell tumor of the testis. *Am J Clin Pathol.* 1980;74:607-19.
2. Plata C, Algaba F, Andujar M, Nistal M, Stocks P, Martinez JL, Nogales FF. Large cell calcifying Sertoli cell tumour of the testis. *Histopathology.* 1995;26:255-9.
3. Blix GW, Levine LA, Goldberg R, Talerman A. Large cell calcifying Sertoli cell tumor of the testis. *Scand J Urol Nephrol.* 1992;26:73-5.
4. Perez-Atayde AR, Nunez AE, Carroll WL, Murthy AS, Vaitukaitis JL, Watson DJ, Bauer SB, Kozakewich HP. Large-cell calcifying sertoli cell tumor of the testis. An ultrastructural, immunocytochemical, and biochemical study. *Cancer.* 1983;51:2287-92.
5. Tetu B, Ro JY, Ayala AG. Large cell calcifying Sertoli cell tumor of the testis. A clinicopathologic, immunohistochemical, and ultrastructural study of two cases. *Am J Clin Pathol.* 1991;96:717-22.
6. Horn T, Jao W, Keh PC. Large-cell calcifying Sertoli cell tumor of the testis: a case report with ul-

trastructural study. *Ultrastruct Pathol.* 1983;4:359-64.

7. Kratzer SS, Ulbright TM, Talerman A, Srigley JR, Roth LM, Wahle GR, Moussa M, Stephens JK, Millos A, Young RH. Large cell calcifying Sertoli cell tumor of the testis: contrasting features of six malignant and six benign tumors and a review of the literature. *Am J Surg Pathol.* 1997;21:1271-80.

## Left mesocolic hernia presenting as an abdominal lump in an adult

**To the Editor:** Mesocolic hernias are rare congenital abnormalities caused by malrotation of the mid-gut and entrapment of the major part of the small gut within a peritoneal sac formed by the developing mesentery of the descending colon.<sup>1</sup> They present with chronic digestive symptoms or with acute intestinal obstruction, gangrene or perforation of the gut.<sup>2</sup> They

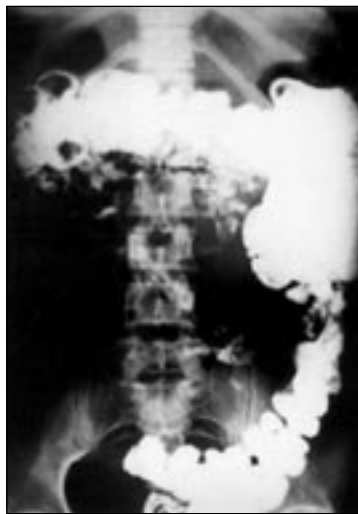are mostly diagnosed incidentally at laparotomy for other conditions or at autopsy.<sup>3</sup>

We describe an adult male with left-sided mesocolic hernia, presenting with chronic atypical abdominal pain and dyspeptic symptoms along with a very unusual finding of a fairly large and extremely mobile abdominal lump. A 40-year-old man presented with acute colicky abdominal pain along with bilious vomiting for 12 hours and a history of episodic abdominal pain and dyspepsia since childhood. For the last 3 months he could feel a lump in the left upper abdomen, mostly during the episodes of pain. Physical findings included an extremely mobile, globular, slightly tender mass about 10 cm in diameter, in the left upper quadrant (LUQ) of

the abdomen. Total blood count and biochemical parameters were normal. Straight x-ray of the abdomen showed dilated loops of small gut in the LUQ. An upper GI barium study, done after conservative management and which relieved his obstructive symptoms, revealed conglomerated loops of small gut in the LUQ of the abdomen, a caecum at a higher level than normal and to the left of midline (Figure 1). Exploration revealed almost  $\frac{2}{3}$  of the small gut encapsulated in the LUQ within a peritoneal sac formed by the descending mesocolon, after gaining entry through a ring below the fourth part of the duodenum. An engorged inferior mesenteric vein (IMV) formed the anterior border of the neck of the sac while the inferior mesenteric artery coursed along the left side of the sac. The ascending colon did not show retroperitoneal fixation.

The entrapped, viable small gut was brought to the right side through the hernial ring after skeletonizing the IMV; the redundant sac was excised after closing the hernial ring. Appendicectomy was also performed. Postoperative recovery was uneventful.

Mesocolic hernias are a rare congenital internal hernia arising from an error of rotation of the midgut when the small bowel invaginates into the mesocolon as the later undergoes rotation and retroperitoneal fixation. Failure of rotation of the pre-arterial segment of the midgut around the superior mesenteric artery in the presence of normal rotation of the post-arterial segment results in right mesocolic hernia, where the small gut remains trapped behind the right mesocolon, in the right upper quadrant of the abdomen.<sup>4</sup> On the other hand, left mesocolic hernia, as in our case, results when



**Figure 1.** Barium-filled loops of small gut in the left upper quadrant of the abdomen.

the small bowel rotates to the left superior portion of the abdominal cavity between the IMV and the retroperitoneum, and during this process invaginates an avascular portion of the descending mesocolon before the later gets fixed to the retroperitoneum.<sup>4</sup> Thus the IMV forms the anterior margin of the narrow hernial ring.

Congenital mesocolic hernias and herniations into one of the paraduodenal fossae are two distinct clinical entities. The later results from herniations into small peritoneal recesses formed due to abnormal fixation of the fourth part of duodenum.<sup>4</sup> In either case, preoperative diagnoses of these internal hernias are difficult.<sup>2,3</sup>

Though in this reported case the herniated loops of small gut could be reduced easily, it may not be so easy. Sometimes the hernial orifice may be difficult to identify and the engorged IMV may make the reduction potentially dangerous.<sup>4</sup> Sometimes it may be necessary to sacrifice the inferior mesenteric vessels to reduce the hernia<sup>5</sup> though most of the time this is unnecessary,<sup>1,2</sup> provided the IMV is properly skeletonized on

the right margin and then reduction is attempted. Following reduction the IMV returns to the left of the base of the mesentery of small bowel. Appendicectomy is always performed to avoid any future diagnostic confusion arising from the abnormal position of the caecum.

**Prosanta Kr. Bhattacharjee**  
**Tamonas Chaudhuri**  
**Sushil R Ghosal**

#### Correspondence

Dr. Prosanta Kr. Bhattacharjee  
R.G. Kar Medical College and Hospital  
Department Of Surgery  
Kolkata-700004 India  
prosantabh@rediffmail.com

#### References

1. Wilkinson GW. Left paraduodenal hernia: a new approach to etiology and treatment. *Can J Surg.* 1971;14:151.
2. Fernando R, Abdon T, Saul D, Jose C. Left paraduodenal mesocolic hernia. *Ann Saudi Med.* 1998;18(4):337-38.
3. Kyaw K. Left mesocolic hernia or peritoneal encapsulation? A case report. *Singapore Med J.* Jan 1998;39(1):30-1.
4. Willwerth BM, Zollinger RM (Jr.), Izant RJ. Congenital Mesocolic (Paraduodenal) Hernia. *Am J Surg.* 1974;128:358-61.
5. Bartlett MK, Wang C, Williams WM. The surgical management of paraduodenal hernia. *Ann Surg.* 1968;168:249.

#### Re: Nutritional koilonychia in 32 Iraqi subjects

**To the Editor:** In response to the admirable report entitled "Nutritional koilonychia in 32 Iraqi subjects" by professor Taher Q. Al-Dabbagh and Khalid G. Al-Abachi, that was published in your March-April 2005 25(2) issue, I wish to convey the following comment:

In 1908 Osler described blue sclerae in iron deficient undernourished teen-age girls. In 1971,

Agnoletto described the same sign being used in diagnosis of hookworm anemia. These observations were later confirmed and explained by Karla et al in a research report published in the November 29, 1986 issue of the *Lancet*. After confirming the relationship of blue sclerae to iron deficiency anemia, the authors biochemically rationalized the etiologic association between iron deficiency and blue sclerae by presenting the fact that iron, in addition to vitamin C, oxygen and ketoglutarate, is essential to the conversion of proline to hydroxylproline. The latter constitute 14% of the structure of collagen and 2% of elastin. They moreover disclosed that fibroblasts in culture do not synthesize collagen in the presence of iron chelating agents. Thus, iron deficiency appears to impair collagen synthesis, which in turn leads to thinning of the sclera through which the choroids can be seen, making it look blue.

Realizing the essential role of iron in collagen synthesis makes it very likely that its deficiency leads to defective synthesis of nails, hence, their thinning and later on hollowing (koilonychia), in the same way its deficiency does with the sclerae. These reasons substantiate the long held idea of iron deficiency as a cause for koilonychias. However, this does not deny the role of other nutritional factors such as sulphur-containing amino acid deficiency that was proposed by the above report, confirming the predating Jalili-Kassab concept (1959). Having no significant iron deficiency in the above report is likely due to the non-homogeneity (randomization of the studied sample or to the reduction in incidence of iron deficiency in the Iraqi community in comparison to animal protein deficiency. This can be attributed to better means of diagnosing and treating chronic blood loss states

like duodenal ulcers, ulcerative colitis, gluten enteropathy and hookworm infection in addition to the fact that iron resources, such as the cheap green vegetables, are more readily available, and supplemental iron pills used to be dispensed freely to pregnant and nursing women in the primary care centers even during the embargo period.

In conclusion the report oriented us to the presence of another cause of nutritional koilonychia in addition to the old well known one (iron deficiency), a cause that may work alone or in conjunction with the latter.

**Nabeel Najib Fadhil, CABM**

Department of Medicine  
Ninevah Medical College  
Mosul, Iraq

nabeelnajibfadhil@yahoo.com