

with close follow-up and monitoring. This is especially important because ribavirin induced hemolysis can be potentiated post-OLT. In fact, in our series, the average dose of ribavirin was well below the recommended dose for immunocompetent patients.⁹

The pathogenesis of post-OLT cholestatic hepatitis in recurrent HCV infection after liver transplantation is not known. The presence of high posttransplant viral loads suggests a direct cytopathic effect of the virus (2). However, the seeming discordance between virological and clinical response in our series does not support this phenomenon. Di Martino and co-workers have recently described a decrease in the intrahepatic HCV-RNA levels over time that was associated with a decrease in the amount of immunosuppression (8). They postulated that progression of HCV-related liver disease in recurrent HCV infection may result from a host response to an early significant viremia rather than solely from a direct cytopathic effect. Whether this mechanism of viral pathogenicity is at work in those with cholestatic hepatitis is not known. One possibility is that cytopathic injury occurs with early viremia and the disease process may be maintained and perpetuated by a host immune-mediated process. It is certainly attractive to postulate that if this mechanism of viral pathogenicity in severe recurrent cholestatic hepatitis C were true, early treatment to prevent this significant early viremia may prevent the onset of disease or decrease the severity of recurrent cholestatic hepatitis C.

In summary, despite early virological response to a combination of interferon α 2b and ribavirin, patients with severe recurrent cholestatic hepatitis C described in this series continued with their progressive course suggesting a discor-

dance between virological response and clinical response. Although combination of interferon α 2 b and ribavirin was tolerated; more data are needed to define the potential efficacy, safety and optimal timing of this regimen in the post-transplant setting.

REFERENCES

1. Berenguer M, Wright TL. Hepatitis C and liver transplantation. *Gut* 1999; 45 (2): 159.
2. Doughty AL, Spencer JD, Cossart YE, McCaughan GW. Cholestatic hepatitis after liver transplantation is associated with persistently high serum hepatitis C virus RNA levels. *Liver Transplant Surg* 1998; 4 (1): 15.
3. Gane EJ, Portmann BC, Naoumov NV, et al. Long-term outcome of hepatitis C infection after liver transplantation [see comments]. *N Engl J Med* 1996; 334 (13): 815.
4. Schluger LK, Sheiner PA, Thung SN, et al. Severe recurrent cholestatic hepatitis C following orthotopic liver transplantation. *Hepatology* 1996; 23 (5): 971.
5. Taga SA, Washington MK, Terrault N, Wright TL, Somberg KA, Ferrell LD. Cholestatic hepatitis C in liver allografts. *Liver Transpl Surg* 1998; 4 (4): 304.
6. Bizollon T, Palazzo U, Ducerf C, et al. Pilot study of the combination of interferon alfa and ribavirin as therapy of recurrent hepatitis C after liver transplantation [see comments]. *Hepatology* 1997; 26 (2): 500.
7. Ong JP, Barnes DS, Younossi ZM, et al. Outcome of de novo hepatitis C virus infection in heart transplant recipients. *Hepatology* 1999; 30 (5): 1293.
8. Di Martino V, Saurini F, Samuel D, et al. Long-term longitudinal study of intrahepatic hepatitis C virus replication after liver transplantation. *Hepatology* 1997; 26 (5): 1343.
9. Steedman S, Younossi Z. Hepatitis C: an update on the silent epidemic. *J Clin Gastroenterol* 2000; 30 (2): 125.

Received 29 June 2000.

Accepted 23 October 2000.

THE DIAGNOSTIC CHALLENGE OF PULMONARY KAPOSI'S SARCOMA WITH PULMONARY TUBERCULOSIS IN A RENAL TRANSPLANT RECIPIENT: A CASE REPORT

AYMAN B. KRAYEM,¹ LAYLA S. ABDULLAH,² ESSAM A. RAWEILY,² SIRAJ O. WALI,^{1,5}
MOHAMMAD M. RAWAS,³ YASSEEN S. SAMMAN,¹ AND ABDULNASSIR A. BATOUK⁴

Pulmonary Section, Department of Medicine, Pathology Department, Radiology Department, and Surgery Department, King Khalid National Guard Hospital, Jeddah 21423, Saudi Arabia

We report a case of a 39-year-old, HIV-negative, post renal transplant patient who developed mucocutaneous Kaposi's sarcoma with lung parenchymal involvement and concurrently culture proven pulmonary tuberculosis. To the best of our knowledge, this is the

first case report of this combination, which presented with cavitating lung nodules and responded well to withdrawal of immunosuppressive drugs beside anti-tuberculous treatment.

INTRODUCTION

Moriz Kaposi in 1872 first described five patients presenting with "sarcoma idiopathicum multiple hemorrhagicum" (1). Kaposi's sarcoma (KS) is a multicentric, low-grade tumor that usually begins with the development of violaceous skin lesions and is associated with the presence of human herpesvirus 8 (2). KS is the most common malignancy associated with human immunodeficiency virus (HIV) infection and occurs in approximately 6–20% of HIV-infected patients (3). It has also been described in immunocompromised patients, particularly after renal transplantation, in which cutaneous

¹ Pulmonary Section, Department of Medicine, King Khalid National Guard Hospital, Jeddah.

² Pathology Department, King Khalid National Guard Hospital, Jeddah.

³ Radiology Department, King Khalid National Guard Hospital, Jeddah.

⁴ Surgery Department, King Khalid National Guard Hospital, Jeddah.

⁵ Address correspondence to: Dr. S. O. Wali, Pulmonary Section, Department of Medicine, King Khalid National Guard Hospital, Jeddah 21423 P.O. Box 9515, Saudi Arabia. E-mail: bintashfeen@yahoo.com.

involvement is the most salient finding (4, 5). In patients with known KS who present with a respiratory problem, up to 50% are due to parenchymal involvement with KS (6). Infectious and noninfectious pulmonary disorders in immunocompromised patients can simulate the radiological manifestations of pulmonary KS. We report an HIV-negative, immunosuppressed patient with pulmonary KS as well as pulmonary tuberculosis, presenting with minimal respiratory symptoms but remarkable radiological abnormalities. This report highlights the dilemma in diagnosing such unique pulmonary complications and reviews the management of immunosuppression-related KS.

CASE REPORT

A 39-year-old Saudi male, 20 packs/year smoker, who is a renal transplant recipient for 14 years, presented with a 3-month history of fever, night sweats, poor appetite, weight loss, and dry cough. The patient had occasional high-grade fever associated with night sweat. His appetite was poor, and he developed significant weight loss. There was no history of shortness of breath, hemoptysis, or chest pain. He was maintained on 150 mg of cyclosporin and 20 mg of prednisolone daily, since his renal transplant. He had been hypertensive for the last 10 years, taking 10 mg of amlodipine daily. He had no history of diabetes mellitus, tuberculosis, alcohol intake, or risk factors for HIV infection. He denied any contact with patients with tuberculosis or recent travel. The systemic review was otherwise unremarkable.

Physical examination revealed Cushingoid features. He was ill looking, febrile, and pale. Multiple skin lesions were present over his left shoulder, trunk, and lower limbs. The largest was on his right lower abdomen: 10×6 cm, dark red, raised, and nontender, with well-defined irregular margins. A cherry-red, 3×2-cm, fungating, painless mass was present on the right side of the hard palate. There were no palpable lymph nodes. Chest examination revealed normal vesicular breath sounds and abdominal examination showed no organomegaly. His proximal muscles showed mild wasting with slightly reduced power.

Investigations revealed normochromic, normocytic anemia with hemoglobin of 10.9 g/dl and an erythrocyte sedimentation rate (ESR) of 98 mm/1 hr. Urea was normal but creatinine was raised to 189 μ mol/l. Serum electrolytes were normal, apart from low bicarbonate of 18 mmol/l. Herpes simplex IgG antibody titer was 1:21,000 with a negative IgM antibody titer. HIV serology was negative. Chest x-ray showed multiple ill-defined nodular opacities, predominantly distributed peripherally in the middle zone. Computerized tomography (CT) of the chest confirmed the nodular shadows, which had a tendency toward peripheral distribution. The nodules were 0.5–2 cm in size, with irregular but well-defined margins mostly along the bronchovascular bundles. No pleural effusion or intrathoracic lymphadenopathy was found (Fig. 1).

The histopathology of a skin biopsy from the abdominal wall lesion was consistent with KS. In view of the close association between KS and immunosuppressive agents, the dose of cyclosporin was reduced to 100 mg daily. One week later the patient's fever disappeared; his appetite improved and he had started to gain weight. Flexible bronchoscopy was performed and there was no evidence of endobronchial KS. The bronchoalveolar lavage (BAL) deposit was positive for

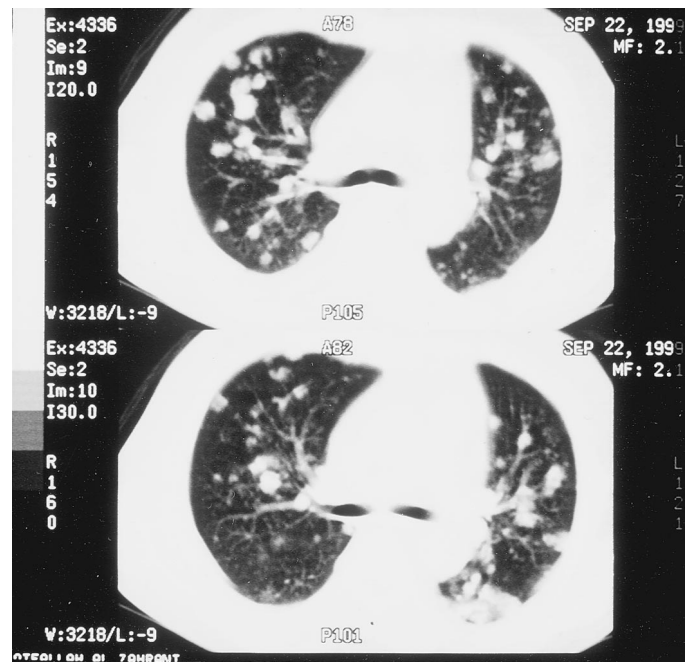


FIGURE 1. CT scan of the chest showing bilateral peripheral nodular shadows of variable sizes mostly along the bronchovascular bundles.

acid-fast bacilli by Ziehl-Neelsen stain and *Mycobacterium tuberculosis*-DNA (MTB-DNA) using a polymerase chain reaction. Special stains for *Pneumocystis carinii* and fungi were negative. The patient was started on four antituberculous medications, including rifampicin, isoniazid, ethambutol, and pyrazinamide. Because his radiological picture was atypical of pulmonary tuberculosis, a fine needle aspiration biopsy of a pulmonary nodule was performed under CT guidance. Cytological preparations showed hypocellular smears with two loose aggregates of spindle cells with elongated, slightly hyper-chromatic nuclei. No granulomas were identified. The findings were highly suggestive of KS.

Three weeks after starting antituberculous therapy, the patient restarted to have low-grade fever, weakness, poor appetite, and a weight loss of 2 kg. However, his skin lesions continued to show regression. Renal function was stable and the ESR was still elevated. A repeat chest x-ray demonstrated mild regression in the nodular infiltrate. Repeated high resolution CT (HRCT) of the chest showed development of new nodular shadows and regression of some of the previously existing nodules. However, some of the nodules showed clear cavitation (Fig. 2). Accordingly, the patient underwent video-assisted thoracoscopic wedge biopsy of the lung. The histopathological examination revealed multiple caseating granulomas with acid-fast bacilli. In addition, spindle cell proliferations separated by slit like spaces, concentrated mostly around the bronchovascular bundles, and stained positive for endothelial markers, including CD34 was diagnostic for KS; hence, pulmonary Kaposi's sarcoma with tuberculosis was confirmed.

The patient was subsequently managed with 50 mg of cyclosporine a day and continued on antituberculous medications for a period of 6 months. Eight weeks after commencing antituberculous therapy, BAL culture became positive for

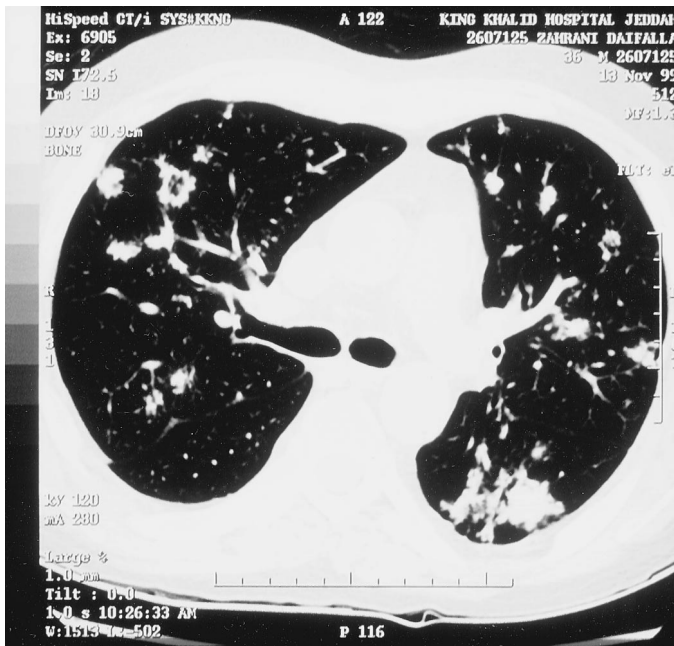


FIGURE 2. HRCT of the chest showing cavitating lung nodules.

MTB, which was sensitive to first line antituberculous agents; hence, ethambutol and pyrazinamide were stopped. After 11 months, the patient showed significant improvement in appetite and energy; he gained 7 kg in body weight and remained afebrile. His skin and oral lesions remarkably regressed and his renal function remained stable. Repeat chest radiograph was normal, and HRCT scan of the chest showed remarkable regression of the multinodular pattern and disappearance of the cavitations (Fig. 3).

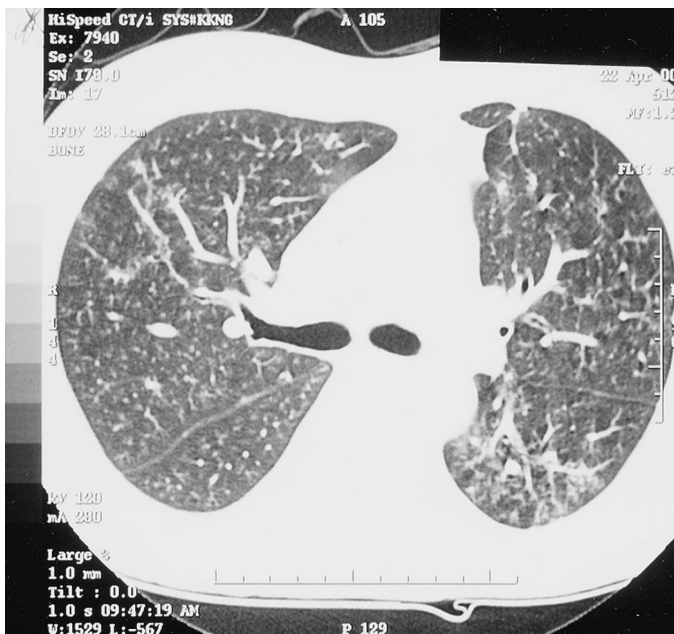

FIGURE 3. HRCT of the chest showing remarkable regression of the cavitating nodules.

DISCUSSION

A marked increased incidence of malignancy in transplant recipients is well recognized. The incidence of posttransplantation KS has varied among different reports and ranged from 1.3–6% (4, 5). In a review of 8724 de novo malignancies that occurred in 8191 organ transplant recipients, Kaposi's sarcoma accounted for 5.7% and was most common in Arab, African, Italian, Jewish, and Greek patients (7). Qunibi et al. (8) from Saudi Arabia reported a similar incidence of 5.3%, making KS the most common tumor in post renal transplantation. In another local study, among 350 recipients of renal transplants, 12 (3.4%) developed Kaposi's sarcoma and 2 (16.6%) presented primarily with lung involvement (9).

Cyclosporine-treated patients were noted to have a higher incidence of KS compared with patients treated with conventional immunosuppressive agents (4). This, together with the high incidence of tuberculosis after renal transplant in Saudi Arabia (10), might have exposed our patient to a greater risk of developing both diseases simultaneously. In a nation-wide study in Saudi Arabia based on Mantoux test, al-Kassimi et al. (11) placed the Jeddah region (where our patient is from) as a region of high prevalence of tuberculosis (20%), compared with 6% for the national average. The incidence, however, of tuberculosis in the Jeddah region was reported to be 63.4 per 100,000 (12), which is higher than that reported for the whole country for the same year (18.6 per 100,000) (12).

Approximately one-third of KS patients has clinically evident pulmonary disease, and 50% have pulmonary involvement at autopsy (4, 13). Most of the affected patients present with shortness of breath, fever, cough, chest pain, and hemoptysis, whereas others may be asymptomatic but have an abnormal chest x-ray (6, 13). The radiographic findings can vary from a normal chest radiograph to nodular opacities associated with hilar adenopathy, interstitial or alveolar opacity, and pleural effusion (14). These findings are nonspecific and may be confused with findings related to pulmonary infections (6). In a patient with known KS who develops either changing symptoms or new roentgenographic findings, an attempt must be made to rule out an associated infectious process.

The role of the CT scan in diagnosing intrathoracic KS has been evaluated in several studies and found to be more specific than routine roentgenograms for identifying pulmonary KS (14). In the absence of concomitant pulmonary infections, the main signs for intrathoracic KS were numerous nodules, bronchovascular thickening, tumoral masses, and pleural effusion (15). The nodular pattern observed in the initial CT scan of our patient was in keeping with the most common radiological manifestations of this malignancy (14, 15). Pulmonary KS does not usually cavitate, however, there has been one report in the literature of cavitating pulmonary KS associated with non-Hodgkin's lymphoma affecting the lung in a patient with acquired immune deficiency syndrome (16). Therefore, searching for concomitant infectious or tumoral pathology is essential whenever there is a cavitary lung lesion as in our patient. Invasive procedures are usually required to diagnose such pulmonary complications whenever the diagnosis is in doubt.

The management of posttransplantation KS has been based on the reduction or cessation of immunosuppression, because disease progression has been observed when immu-

nosuppression was continued (4, 5). Interestingly, the cessation of immunosuppression does not always result in graft loss (4). This has been postulated to be related to the depletion of CD4 T lymphocytes, which results in immune tolerance to the allograft even with minimal immunosuppression (17). Montagnino et al. (4) reported complete remission in nine patients and partial remission in two after reduction or withdrawal of immunosuppressive therapy. In his report, 69% of the patients remained dialysis-free after a mean follow-up period of 35 months. Using this approach for our patient, we have achieved a remarkable clinical and radiological regression of the cutaneous and pulmonary KS lesions and remained dialysis-free after 12 months of follow up, despite being on low-dose cyclosporine (50 mg per day).

CONCLUSION

The case that we are reporting highlights the dilemma in reaching an accurate diagnosis in patients presenting with pulmonary complications of immunosuppression, where the coexistence of more than one pathology is well recognized. To our knowledge, this is the first case report of coexistence of pulmonary Kaposi's sarcoma and pulmonary tuberculosis in an HIV-negative, renal transplant recipient who presented with cavitary lung lesions and responded well to reduction of immunosuppression and institution of antituberculous medications. We recommend that in an immunosuppressed patient with an atypical presentation of a specific complication, further work-up is warranted to rule out a co-existing pathology.

REFERENCES

1. Kaposi M. Idiopathisches multiples pigmentsarkom der haut. Arch Dermatol Syphiloe 1872; 4: 265.
2. Chang Y, Cesarman E, Pessin MS, et al. Identification of herpesvirus-like DNA sequences in AIDS-associated Kaposi's sarcoma. Science 1994; 266: 1865.
3. Serraino D, Franceschi S, Tirelli U, Monfardini S. The epidemiology of acquired immunodeficiency syndrome and associated tumours in Europe. Ann Oncol 1992; 3: 595.
4. Montagnino G, Bencini PL, Tarantino A, Caputo R, Ponticelli C. Clinical features and course of Kaposi's sarcoma in kidney transplant patient: report of 13 cases. Am J Nephrol 1994; 14: 121.
5. Margolius L, Stein M, Spencer D, Bezwoda WR. Kaposi's sarcoma in renal transplant recipients: experience at Johannesburg Hospital, 1966-1989. S Afr Med J 1994; 84: 16.
6. White DA, Matthay RA. Noninfectious pulmonary complications of infection with the immunodeficiency virus. Am Rev Respir Dis 1989; 140: 1763.
7. Penn I. Sarcomas in organ allograft recipients. Transplantation 1995; 60: 1485.
8. Qunibi WY, Barri Y, Alfurayh O, et al. Kaposi's sarcoma in renal transplant recipients: a report on 26 cases from a single institution. Transplant Proc 1993; 25: 1402.
9. Gunawardena KA, al-Hasani MK, Haleem A, al-Suleiman M, al-Khader AA. Pulmonary Kaposi's sarcoma in two recipients of renal transplants. Thorax 1988; 43: 653.
10. Qunibi WY, al-Sibai MB, Taher S, et al. Mycobacterial infection after renal transplantation: report of 14 cases and review of the literature. Q J Med 1990; 77: 1039.
11. al-Kassimi FA, Abdullah AK, al-Hajjaj MS, al-Orainey IO, Bamgboye EA, Chowdhury MN. Nationwide community survey of tuberculosis epidemiology in Saudi Arabia. Tuber Lung Dis 1993; 74: 254.
12. Milaat WA, Ali AS, Afif HA, Ghabrah TM. Epidemiology of tuberculosis in Jeddah region, Saudi Arabia. Saudi Med J 1994; 15: 133.
13. Zibrac JD, Silvestri RC, Costello P, et al. Bronchoscopic and radiologic features of Kaposi's sarcoma involving the respiratory system. Chest 1986; 90: 476.
14. Naidich DP, Tarras M, Garay SM, et al. Kaposi's sarcoma: CT-radiographic correlation. Chest 1989; 96: 723.
15. Khalil AM, Carette MF, Cadranell JL, Mayaud CM, Bigot JM. Intrathoracic Kaposi's sarcoma: CT findings. Chest 1995; 108: 1622.
16. Ko AH, Thomas DL, Gallant JE. Non-Hodgkin's lymphoma and Kaposi's sarcoma causing cavitary lung lesion in a patient with AIDS: an HIV-associated Collision tumor. AIDS 1995; 9: 1195.
17. Qunibi W, Akhtar M, Sheth K, et al. Kaposi's sarcoma: the most common tumor after renal transplantation in Saudi Arabia. Am J Med 1988; 225: 225.

Received 5 June 2000.

Accepted 26 October 2000.

POSTNATAL CYTOKINES AND BOOSTS IMPROVE CHIMERISM AND HEMATOLOGICAL PARAMETERS IN β -THALASSEMIC MICE TRANSPLANTED IN UTERO¹

J. DONAHUE, E. GILPIN, D. YOUNG, AND E. CARRIER²

Departments of Medicine, Pediatrics, Family and Preventive Medicine, University of California San Diego School of Medicine, La Jolla, California

We have developed a murine model of in utero transplantation in nonanemic, β -thalassemic mice to study chimerism, tolerance, and changes in hematological parameters in response to cytokines and postnatal boosts with donor cells. We have documented improved survival of homozygous fetuses by 40% as com-

pared with controls. Low-level, mixed chimerism was improved by postnatal cytokine therapy and boosts and was associated with improvement in hemoglobin levels, reticulocyte counts, and iron stores. Cytotoxicity assays demonstrated higher responses to donor cells in control mice as compared with in utero transplanted animals (at 50:1 effector to target ratios, transplanted mice showed 8.66% target lysis and control mice showed 51.85% target lysis, $P=0.0003$), indicating tolerance. The combination of prenatal tolerance to allogeneic cells with postnatal boosts in primed hosts may become an effective, nontoxic strategy for the improvement of hemolytic anemia in β -thalassemic patients.

¹ This work was supported by Grant #K08HL03603-03 and Grant #HL98-022 from the National Institute of Health, DHHS (E.C.), RMHC Medical Grant (E.C.), and March of Dimes Grant (95-0954).

² Address correspondence to: Ewa Carrier, M.D., UCSD Blood and Marrow Transplantation Division, 9500 Gilman Drive, #0062, La Jolla, CA 92093-0062. E-mail: ecarrier@ucsd.edu.