

A Case Report of Moyamoya Disease Presenting with Chorea

Aysha A. Alshareef, MD, SAUDI BOARD NEUROLOGY

*Department of Internal Medicine, Faculty of Medicine
King Abdulaziz University, Jeddah, Saudi Arabia
dr_ayshareef@hotmail.com*

Abstract. This article presents the case of a twelve-year-old girl with generalized chorea and chronic migraine headaches. Her examination showed generalized chorea with hypotonia. Brain magnetic resonance images showed multiple old ischemic strokes in the frontal and occipital regions, with flow void appearance in the basal ganglia region. Brain magnetic resonance angiography showed collateral channels at the base of the brain with narrowing of the arteries of circle of Willis which is the classic picture of Moyamoya disease.

Keywords: Moyamoya disease, Chorea, Stroke.

Introduction

Moyamoya disease is a chronic cerebrovascular disease characterized by severe bilateral stenoses, or occlusion of the arteries around the circle of Willis with prominent collateral circulation^[1,2]. Involuntary movement disorder including chorea is not a common clinical presentation in Moyamoya disease^[3]. This case report describes a child presented with chorea and chronic migraine headaches diagnosed as Moyamoya disease. It also includes a review of literature related to similar cases.

Correspondence & reprint request to: Dr. Aysha Alshareef
P.O. Box 80215, Jeddah 21589, Saudi Arabia

Accepted for publication: 10 September 2007. Received: 22 May 2007.

Case Report

A twelve-year-old girl was presented to the emergency department with a five-month history of abnormal movements. The abnormal movements involved the upper limbs, lower limbs and trunk. She confirmed a history of slurred speech, gait difficulty with frequent falling attacks and numbness on the right side of the body. The symptoms initially were fluctuating and then became progressive. There was no history of other types of abnormal movements. She denied any history of loss of consciousness, convulsion, memory disturbance, or symptoms of cranial nerve involvement. She is a product of normal delivery with normal natal, antenatal, and postnatal history. She had one attack of febrile convulsion when she was four-years-old. At the age of six she started to have a migraine headache with aura once a month and this was sometimes complicated by transient right hemiparesis. She had a history of frequent tonsillitis. There was no history of rheumatic heart disease, skin rash, psychological problems, joint pain or jaundice. She denied any drug ingestion apart from propranolol for migraine headaches. She was an intermediate school student with good school performance. She lived in Tabuk. There was no history of travel abroad and no family history of similar illnesses. Her mother and father are first-degree relatives. On examination, she was afebrile with normal blood pressure, respiratory rate and pulse rate. Cardiac, chest, gastrointestinal, and rheumatological systems examinations were unremarkable. Neurological examination revealed normal higher functions. Her speech revealed dysarthria with no cranial nerves involvement. Motor examination revealed restless movements which involved upper limbs, lower limbs and trunk; the movements were rapid, jerky, irregular, low amplitude and flit from one part of the body to another which is typical of chorea. There was weakness in the right side of grade 4/5, hypotonia, normal deep tendon reflexes and the plantar responses were down going bilaterally. Her gait was unsteady. Finger to nose test revealed no dysmetria, although there were involuntary movements during the maneuver.

The following investigations were done to rule out any possible causes of chorea which included thyroid function: Antistreptolysin O titre (AS(L)OT), throat culture, lactate, pyruvate, ceruloplasmin level, erythrocyte sedimentation rate, C reactive protein, anti-nuclear

antibodies, anti-DNA titres, Anti-cardiolipin antibodies (ACA), alpha fetoprotein, echocardiogram and blood film. All were within normal limits. The electroencephalogram showed sharp activity over the left frontotemporal area that spread to the right side occasionally. Cranial Magnetic Resonance Imaging Scan (MRI) revealed right frontal and occipital region encephalomalacia (loss of brain tissues), which may indicate old ischemic stroke. It also showed flow void appearance around the basal ganglia. Further evaluation by magnetic resonance angiography demonstrated collateral channels at the base of the brain with stenosis of the arteries around circle of Willis, which is typical of Moyamoya disease (Fig. 1 and 2). The following laboratory tests were done to rule out any other possible causes of ischemic stroke: Protein C and S, homocysteine, anti-thrombin III level, Factor IV Leiden mutation, and sickle cell screen, all were within normal limits.

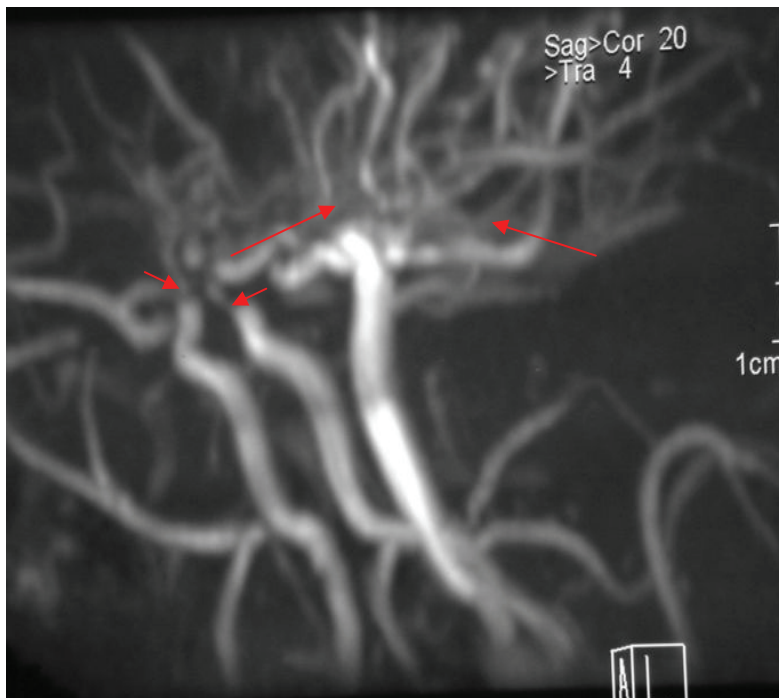

Fig. 1. Magnetic resonance angiogram of the brain, lateral view demonstrates stenosis around The circle of Willis (short arrows) with development of collateral vessels (long arrows), which is a classic of Moyamoya disease.

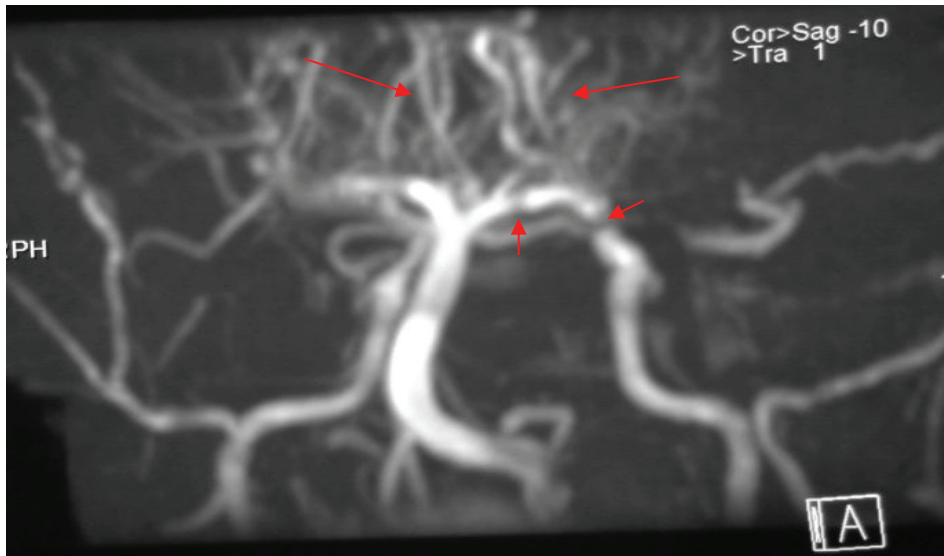


Fig. 2. Magnetic resonance angiogram of the brain, posterior view demonstrates stenosis around the circle of Willis (short arrows) with prominent collateral circulation (long arrows).

After the diagnosis of Moyamoya disease was reached, the patient was started on antiplatelet aspirin 81 mg once per day and haloperidol 1.5 mg twice per day. The next follow-up showed mild improvement but the patient still had gait difficulty; she was referred to neurosurgery for possible surgical intervention, but she did not come back.

Discussion

Moyamoya disease was described initially in Japan in the sixties as (wavering puff of smoke). It was believed to be restricted only to Japan; however, there have now been reports from various parts of the world.

Moyamoya disease is a clinical entity characterized by bilateral occlusion of the internal carotid arteries and the development of collateral arteries^[4]. The etiology of Moyamoya disease has not been clarified. Family history of Moyamoya disease was apparent in 10% of patients in Japan^[5]. It can occur as a primary disease or as a syndrome in association with a variety of conditions (*e.g.*, neurofibromatosis, Down syndrome, vasculitis, radiation, sickle cell anemia, congenital heart disease, Type 1 glycogenosis), yet its pathogenesis remains unexplained^[4]. Histopathological studies revealed stenosis and occlusion

of the main arterial trunk, usually due to fibro cellular thickening of intima^[5,6]. Diagnostic criteria classify the adult cases displaying bilateral occlusive lesion as definitive Moyamoya disease and those exhibiting unilateral involvement as a probable Moyamoya disease^[5,7]. The highest incidence of this disease is in the first decade of life. Initial symptoms manifest as transient ischemic attack, cerebral infarction, and intracerebral hemorrhage, or occasional seizure. An ischemic event is the usual clinical presentation in childhood Moyamoya disease; whereas, the hemorrhagic stroke is more common in adulthood; chorea has rarely been described^[8]. The episodic symptoms of Moyamoya disease may be precipitated by hyperventilation and changes in body temperature.

Several medical treatments (anticoagulation, antiplatelet drugs and corticosteroid) have been tried without benefit. Surgical therapy for Moyamoya disease is recommended in most patients, particularly in light of the ineffectiveness of medical therapy. Surgical treatment is intended to restore the circulation for the ischemic brain area to prevent ischemic stroke and transient ischemic attacks (TIA)^[9]. Surgical therapy of Moyamoya disease can be categorized as: direct revascularization (superficial temporal artery to middle cerebral artery bypass or middle meningeal artery bypass) and indirect revascularization (encephaloduroarteriosynangiosis (EDAS); encephalomyosynangiosis (EMO); encephaloarteriosynangiosis (EAS), duraplexy and omentum transplantation), or a combination of both. It is reported that combined surgery superficial temporal artery to middle cerebral artery bypass (STA-MCA bypass) with EDAS) for pediatric Moyamoya disease was effective in reducing the risk of postoperative ischemic attacks compared with indirect surgery^[3].

Chorea is uncommon abnormal movement; the term chorea is derived from the Greek word – chorea meaning, "dance". This condition consists of irregular, unpredictable, brief and jerky movements that flit from one part of the body to another in a random sequence^[10]. It can be seen in a wide range of disorders. These disorders are classified as follows: inherited and tumor-related disorders, drug-induced, systemic, rheumatic, and vascular-related diseases, and other rare causes^[3]. Chorea is a comparatively rare clinical feature of Moyamoya disease and syndrome^[11]. It has been suggested that 6% of those with Moyamoya disease have chorea^[12,13]. Other types of abnormal movements have been described in patients with Moyamoya disease^[13]. Choreic movement in this disease usually wax and wane and are often triggered by excitement,

emotion, strain or crying. They may be unilateral or bilateral and often appear alternatively in the left and right side^[14].

The pathophysiology of chorea is related to basal ganglia hypoperfusion, which is explained well by marked improvement after bypass surgery of Moyamoya disease.

In the English language literature, the author found 21 case reports describing cases of Moyamoya disease with initial presentation of chorea^[3,8,11-22,25-27]. The summary of these case reports, comparing age, sex and race are presented in Table 1. The age of onset was variable from one year to fifty-five years. The sex distribution showed female predominance with 76%; most of the patients were Japanese.

Table 1. Summary of the reported cases of Moyamoya disease with chorea presentation.

Case no./Author/s	Year	Age	Sex	Race
Case 1/Watanbe <i>et al.</i> ^[14]	1990	4	F	Japanese
Case 2/ Watanbe <i>et al.</i> ^[14]	1990	7	M	Japanese
Case 3/ Watanbe <i>et al.</i> ^[14]	1990	14	F	Japanese
Case 4 /Pavlakis <i>et al.</i> ^[12]	1991	13	M	American
Case 5/Takanshi <i>et al.</i> ^[22]	1993	11	F	Japanese
Case 6 /Pelletier <i>et al.</i> ^[25]	1997	17	F	Japanese
Case 7/Pelletier <i>et al.</i> ^[25]	1997	17	F	Japanese
Case 8/Parmar <i>et al.</i> ^[20]	2000	11	M	Indian
Case 9/Parmar <i>et al.</i> ^[20]	2000	9	F	Indian
Case 10/Unno <i>et al.</i> ^[21]	2000	16	F	Japanese
Case 11/Han <i>et al.</i> ^[13]	2000	29	F	Korean
Case 12/Lyoo <i>et al.</i> ^[19]	2000	22	F	Japanese
Case 13/Shanahan <i>et al.</i> ^[17]	2001	18	F	Irish
Case 14/Hama <i>et al.</i> ^[18]	2001	12	M	Japanese
Case 15/Miura <i>et al.</i> ^[16]	2002	54	F	Japanese
Case 16/Hong <i>et al.</i> ^[8]	2002	20	F	South African
Case 17 /Iwasaki ^[28]	2004	50	M	Japanese
Case 18/Spengos <i>et al.</i> ^[11]	2004	28	F	Greek
Case 19/Watanabe <i>et al.</i> ^[26]	2005	20	F	Japanese
Case 20/Kim <i>et al.</i> ^[27]	2006	1y	F	Korean
Case 21/Zheng <i>et al.</i> ^[3]	2006	15	F	Japanese

Regarding the issue of migraine headaches in this case, it is not clear if it is related to Moyamoya disease or not. The history of transient right side weakness during some of migraine headache attacks raised the possibility of hemiplegic migraine, but transient hemiparesis can be a picture of Moyamoya disease. In literature, four cases of Moyamoya disease have been reported with initial presentation of migraine-like headaches^[4,15,23,24], the age onset was variable from (4-49 years); all of them were females.

Association of migraine and Moyamoya disease, although existing, is infrequent. Therefore, the point of contention over whether it is worth screening patients with migraine headaches for Moyamoya disease must be addressed.

Finally, as was noticed in previous reviews, chorea as a presentation of Moyamoya disease is uncommon, but does exist. Accordingly, Moyamoya disease should be included in the differential diagnosis of chorea movements for possible early intervention in order to prevent further disability.

References

- [1] **Suzuki J, Kodama N.** Moyamoya disease--a review. *Stroke* 1983; **14(1)**: 104-109.
- [2] **Kitamura K, Fukui M, Oka K, Matsushima T, Kurokawa T, Hasuo K.** Moyamoya disease. In: Toole JF, eds. *Handbook of Clinical Neurology 11*. Amsterdam, Netherlands: Elsevier Science Publishing Co; 1989. 293-306.
- [3] **Zheng W, Wanibuchi M, Onda T, Liu H, Koyanagi I, Fujimori K, Houkin K.** A case of moyamoya disease presenting with chorea. *Child Nerve Syst* 2006; **22(3)**: 274-278.
- [4] **Aydin K, Okuyaz C, Gücüyener K, Serdaroğlu A, Akpek S.** Moyamoya disease presented with migrainelike headache in a 4-year-old girl. *J Child Neurol* 2003; **18(5)**: 361-363.
- [5] **Kusaka N, Tamiya T, Adachi Y, Katayama S, Namba S, Tokunaga K, Sugiu K, Date I, Ohmoto T.** Adult unilateral moyamoya disease with familial occurrence in two definitive cases: a case report and review of the literature. *Neurosurg Rev* 2006; **29(1)**: 82-87.
- [6] **Hosoda Y.** Pathology of so-called "spontaneous occlusion of the circle of Willis". *Pathol Annu* 1984; **19(Pt 2)**: 221-244.
- [7] **Fukui M.** Guidelines for the diagnosis and treatment of spontaneous occlusion of the circle of Willis ('moyamoya' disease). Research Committee on Spontaneous Occlusion of the Circle of Willis (Moyamoya Disease) of the Ministry of Health and Welfare, Japan. *Clin Neurol Neurosurg* 1997; **99(Suppl 2)**: S238-S240.
- [8] **Hong YH, Ahn TB, Oh CW, Jeon BS.** Hemichorea as an initial manifestation of moyamoya disease: reversible striatal hypoperfusion demonstrated on single photon emission computed tomography. *Mov Disord* 2002; **17(6)**: 1380-1383.
- [9] **Ueki K, Meyer FB, Mellinger JF.** Moyamoya disease: the disorder and surgical treatment. *Mayo Clin Proc* 1994; **69(8)**: 749-757.

- [10] **Bradley WG, Daroff RB, Fenichel GM, Marsden CD** (Eds). In: *Neurology in Clinical Practice* (3rd ed). Boston: Butterworth-Heinemann, 2004. 327-328.
- [11] **Spengos K, Tsivgoulis G, Toulas P, Vemmos K, Vassilopoulos D, Spengos M**. Hyperventilation-enhanced chorea as a transient ischaemic phenomenon in a patient with moyamoya disease. *Eur Neurol* 2004; 51(3): 172-175.
- [12] **Pavlakis SG, Schneider S, Black K, Gould RJ**. Steroid-responsive chorea in moyamoya diseases. *Mov Disord* 1991; 6(4): 347-349.
- [13] **Han SH, Kim YG, Cha SH, Chung SY**. Moyamoya disease presenting with signing induced chorea. *J Neurol Neurosurg Psychiatry* 2000; 69(6): 833-834.
- [14] **Watanabe K, Negoro T, Maehara M, Takahashi I, Nomura K, Miura K**. Moyamoya disease presenting with chorea. *Pediatr Neurol* 1990; 6(1): 40-42.
- [15] **Park-Matsumoto YC, Tazawa T, Shimizu J**. Migraine with aura-like headache associated with moyamoya disease. *Acta Neurol Scand* 1999; 100(2): 119-121.
- [16] **Miura T, Kobayashi M, Sonoo M, Isii K, Shimizu T**. [An adult case of Moyamoya disease presented with transit hemichorea] *Rinsho Shinkeigaku* 2002; 42(1): 45-47. Japanese.
- [17] **Shanahan P, Hutchinson M, Bohan A, O'Donoghue D, Sheahan K, Owens A**. Hemichorea, moyamoya, and ulcerative colitis. *Mov Disord* 2001; 16(3): 570-572.
- [18] **Hama A, Furune S, Nomura K, Takada Y, Matsushima Y**. [A case of unilateral moyamoya disease with hemichorea] *No To Hattatsu* 2001; 33(2): 166-171. Japanese.
- [19] **Lyo CH, Oh SH, Joo JY, Chung TS, Lee MS**. Hemidystonia and hemichoreoathetosis as initial manifestation of Moyamoya disease. *Arch Neurol* 2000; 57(10): 1510-1512.
- [20] **Parmar RC, Bavdekar SB, Muranjan MN, Limaye U**. Chorea as unusual presenting features in pediatric Moyamoya disease. *Indian Pediatrics* 2000; 37(9): 1005-1009.
- [21] **Unno S, Iijima M, Osawa M, Uchiyama S, Iwata M**. [A case of chorea gravidarum with Moyamoya disease] *Rinsho Shinkeigaku* 2000; 40(4): 378-382. Japanese.
- [22] **Takanashi J, Sugita K, Honda A, Niimi H**. Moyamoya syndrome in a patient with Down syndrome presenting with chorea. *Pediatr Neurol* 1993; 9(5): 396-398.
- [23] **Contamin F, Mignot B, Wesley C, Ollat H, Brandely M, Henry-Biabaud E**. Occlusive arterioathy of circle of Willis with outlined "moyamoya" network in a woman with migraine under oral contraceptive. Regressive course. *Sem Hop* 1983; 59(18): 1387-1392.
- [24] **Bernstien AL**. Hemiplegic migraine and moyamoya disease. *Am J Dis Child* 1993; 147(7): 718-719.
- [25] **Pelletier J, Cabanot C, Lévrier OR, Thuillier JN, Chérif AA**. [Angiodysplasia of moyamoya type disclosed by choreic involuntary abnormal movements during oral contraception. Apropos of 2 cases] *Rev Neurol (Paris)* 1997; 153(6-7): 393-397. French
- [26] **Watanabe C, Oishi T, Yamamoto T, Sasaki K, Tosaka M, Sato T, Kobayashi H, Takayama S, Sato A, Iwata M, Uchigata Y, Iwamoto Y**. Chorea and Broca aphasia induced by diabetic ketoacidosis in a type 1 diabetic patient diagnosed as Moyamoya disease. *Diabetes Res Clin Pract* 2005; 67(2): 180-185.
- [27] **Kim YO, Kim TS, Woo YJ, Kim CJ, Oh CK**. Moyamoya disease-induced hemichorea corrected by indirect bypass surgery. *Pediatr Int* 2006; 48(5): 504-506.
- [28] **Iwasaki Y, Iwasaki Y, Nakamura T, Hamada K**. [Late-onset of idiopathic paroxysmal kinesigenic choreoathetosis: a case report] *Rinsho Shinkeigaku* 2004; 44(6):365-8. Japanese.

الحركة اللاإرادية الرقصية كعرض لمرض المويامويا

عائشة عبدالملك الشريف

قسم الباطنية، كلية الطب، جامعة الملك عبدالعزيز

جدة - المملكة العربية السعودية

المستخلص . في هذه الورقة نعرض حالة طفلة تبلغ من العمر اثنا عشر عامًا تعاني من حركات رقصية، وصداع الشقيقة المزمن، ولقد أجريت لها أشعة الرنين المغناطيسي للدماغ والشرابين، فاتضح وجود جلطات متعددة في الدماغ. وضيق في الشرايين، مما أثبت تشخيص مرض المويامويا.

